

Small Ruminant Abortion Investigations: Diagnostic considerations and sampling recommendations

Reproductive failure workups in any species are a regular source of frustration for producers and clinicians alike. These cases suffer from an unfortunate low diagnostic success rate. In the absence of clinically dramatic abortion storms, significant frustration can arise when weighing the costs and benefits of performing diagnostics on sporadic losses. Small ruminant reproductive submissions at Iowa State University Veterinary Diagnostic Laboratory do boast a higher rate of etiologic diagnosis than other production animal species (59%, Figure 1); however, a large proportion are still ruled to be idiopathic or are attributed to agents/conditions of low or uncertain herd-level significance. Major contributors to this somewhat misleading “diagnostic failure” rate can include incomplete sampling, testing, and the myriad non-infectious causes of reproductive failure. As such, diagnostic outcomes can be optimized by pairing purposeful investigation of epidemiology and herd health background with comprehensive tissue sampling and targeted test selection.

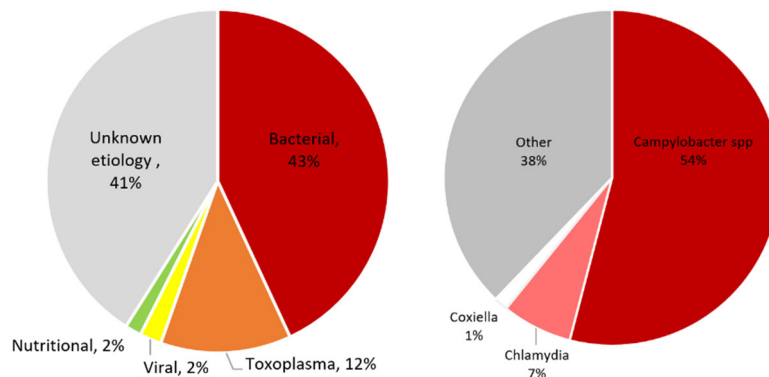


Figure 1: Summary of etiologic diagnoses for caprine and ovine abortions received at ISU-VDL from 2019 to 2023. Diagnoses are represented as percentages of total submissions (left, n =195), and bacterial etiologies (right, n=74).

When reproductive losses occur, a thorough history and understanding of client goals, paired with examination of dams and fetal tissues can help inform the need for further action. Abortion rates above 5% and synchronous losses in multiple animals, particularly if localized to a single pen or age group, are concerning for an infectious disease outbreak and should be investigated further. Direct reproductive risk factors, such as open herd inventory and co-mingling of stock from unknown backgrounds can be further superimposed on chronic management gaps such as lapsed vaccination protocols, mixed-parity housing, poor hygiene, crowding, and inadequate nutritional support or shelter for climate conditions. A confluence of management risk factors can trigger or exacerbate reproductive loss events. Affected dams should be examined as a group and as individuals to screen for common themes in age, body condition, penning, and evidence of clinical disease. Abortions affecting predominantly naïve animals with no clinical signs preceding reproductive loss are suspect for endemic/enzootic agents (*Toxoplasma*, *Campylobacter*, *Coxiella*). Meanwhile, herds with outbreaks of clinical disease (respiratory, enteric, systemic) may experience abortions across all parities due to stress, maternal pyrexia, or opportunistic bacteremia. In contrast, sporadic but persistent losses in the absence of infectious disease pressure may require a more intensive investigation of management and nutrition.

Gross examination of fetuses and placenta can help prioritize differentials and suggest whether infectious abortion is likely. Given the elevated risk for zoonoses, pregnant and immunosuppressed individuals should be cautioned against handling these tissues.

- **Fetal body:** Examination of the body can be very informative as to the timing and possible cause of reproductive loss (Figure 2).
 - *Degree and character of fetal decomposition:* Fetuses should be evaluated for gestational age (size, haircoat) and evidence of in-utero decomposition. Acute fetal infection and immediate expulsion, can present with fresh tissues and be difficult to differentiate from stillbirth in late-term losses. If there is a prolonged interval between fetal death and expulsion, recognizing markers of autolytic vs putrefactive fetal decay can help prioritize differentials. Aseptic decomposition of the fetal body with gradual progression through fetal mummification can be a sign of viral or protozoal involvement. In particular, Toxoplasmosis can present with step-wise fetal death and mummification. In contrast, a macerating, emphysematous, foul-smelling fetus at time of abortion is strongly suggestive of bacterial colonization of the fetoplacental unit, either hematogenously or via opportunistic trans-cervical ascent.
 - *Fetal anomalies:* Fetal malformation can be a function of spontaneous mutations or heritable defects, however, infectious, toxic, or nutritional causes should be considered based on the appearance and epidemiology of anomalies. Certain neurotropic infectious agents (e.g. Cache Valley virus) can induce severe muscle atrophy and secondary skeletal aberrations, including arthrogryposis, scoliosis, and craniofacial defects. Nutritional intervention may be warranted with increased rates of cleft palates (vitamin A) and goiters (iodine).
 - *Post-natal death:* Wearing of the eponychium and gross observation of lung inflation or buoyancy in liquid indicate live birth, rather than abortion or stillbirth. Presence or absence of colostrum (successful nursing) or dirt/wool/plant material (unsuccessful nursing attempts) in the stomach can provide further evidence that death was not directly related to parturition. Trauma, exposure, mis-mothering become differentials in these cases.

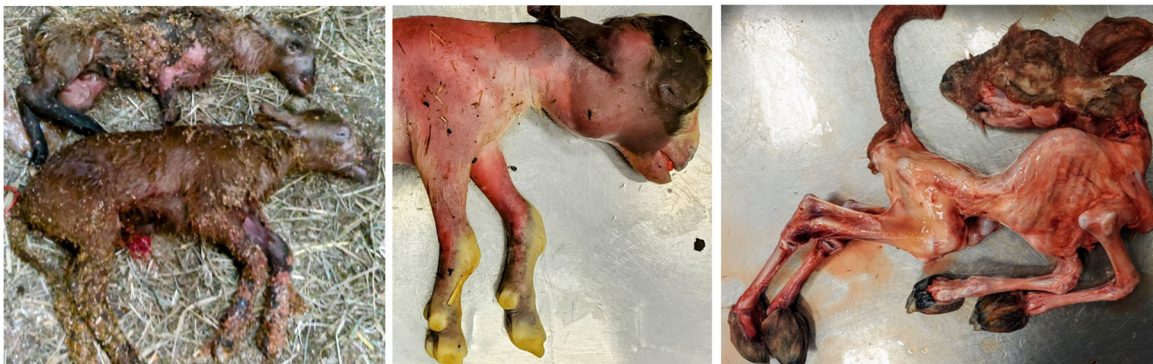

Figure 2: Examples of etiologically significant findings in fetal gross examination. Left: Asynchronous fetal death with presentation of a full-term stillborn fetus and a partially mummified immature twin associated with a *Toxoplasma* infection. Middle: Full-term fetus with sparse haircoat, superior brachygnathia and prominent bilateral firm enlargement of the thyroid (goiter) due to gestational iodine deficiency. Right: Fetus with arthrogryposis and scoliosis. Skin has been removed to demonstrate profound denervation muscle atrophy as a consequence of Cache Valley Virus infection.

- **Placenta:** Fetal membranes can be gently rinsed to remove debris and screened for evidence of infection (Figure 3). Normal small ruminant placentas feature a thin transparent intercotyledonary membrane with prominent chorioallantoic blood vessels. Adjacent cotyledons should be of similar size and color, although progressively decreasing size and necrotic tips can be observed at the distal extremes. Color can vary depending on duration of retention and degree of blood breakdown, however, sharp variation in cotyledon color or

adherence of exudate should be noted as abnormalities. Thickening or adherent exudate on cotyledons and intercotyledonary membrane is supportive of bacterial placentitis; *Campylobacter*, *Coxiella*, *Chlamydia*, and *Brucella* should be considered as primary differentials. In contrast, Toxoplasmosis, can cause pinpoint-mineralization and necrosis which appear like rice grains on cotyledons only. It is imperative that chorioallantoic placenta be submitted, both fresh and formalin-fixed. Submission of the amniotic membranes alone can lead to under-diagnosis.

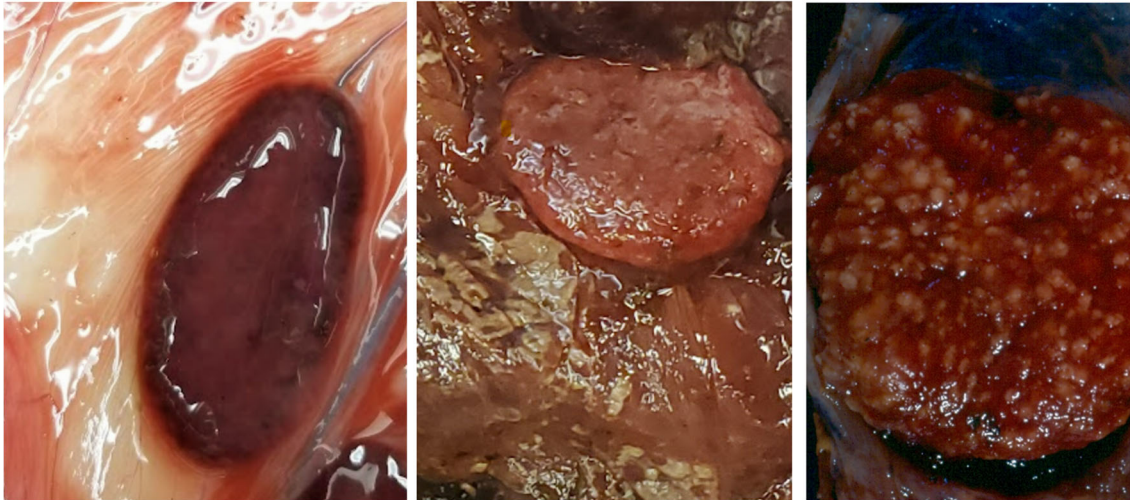


Figure 3: Examples of gross placental examination findings. Left: Normal placenta should have thin and transparent intercotyledonary membrane. Cotyledons should be relatively uniform in color and size. Middle: Thickened opaque intercotyledonary placenta with adherence of tan exudate is strongly suggestive of bacterial placentitis. Right: Miliary necrosis and mineralization in the cotyledon with an unremarkable, thin intercotyledonary placenta is characteristic of *Toxoplasma* infection.

If diagnostics appear warranted, the submission of a complete sample set is critical to ensuring diagnostic success. Certain agents may *only* be found in the fetus (e.g. Cache Valley virus), others *predominantly* in the placenta (*Coxiella*), while some viral agents may only leave a serologic footprint. In the absence of all three puzzle pieces (fetus, placenta, serum), it may be impossible to definitively rule out infectious contribution to fetal death, and submission of multiple litters may be necessary to ensure representation of herd-level concerns. Both whole chilled fetuses and placentas can be submitted for culture, PCR, and histopathologic examination. Viral infections can be cleared and may no longer be detectable in fetal tissues at the time of abortion/birth. If suspected, serologic screening for prior infection (fetus) or exposure (dam) can be performed on fetal thoracic fluid or maternal serum, respectively. Table 1 contains a summary of recommended samples and routine testing modalities for small ruminant abortion investigation.

Finally, the absence of infectious agent detection does not necessarily constitute a diagnostic failure. Non-infectious causes of reproductive losses can include maternal stress (movement, weather, bullying), nutritional imbalances (trace minerals, vitamins, calories), metabolic morbidity (ketosis, hypocalcemia), dystocia, and occasional toxicities. Failure to diagnose infectious disease in a complete abortion submission can be immensely informative, in that 1) it indicates that there is not a current risk of infectious disease to the rest of the flock, 2) there is not an indication for antibiotic intervention, and 3) it suggests a need to examine individual animal and management factors. Available diagnostics and submission guidelines can be found on the ISUVDL website (<https://vetmed.iastate.edu/vdl>). Telephone or email inquiries are always welcome: 515-294-1950, or isuvdl@iastate.edu.

Table 1: Recommended samples for small ruminant reproductive loss workup		Routine testing modalities at ISUVDL
Fetal tissues	Whole refrigerated fetus OR fresh and fixed: brain, lung, heart, thymus, liver, spleen, kidney, diaphragm, tongue, adrenal gland, ear notch	Histopathology, culture Small ruminant abortion panel PCR: Border disease, Cache valley virus, <i>Campylobacter jejuni</i> , <i>Campylobacter fetus</i> , <i>Coxiella burnetii</i> , <i>Chlamydia abortus</i> , <i>Toxoplasma</i> , <i>Caprine herpesvirus 1</i> Additional PCR tests: <i>Leptospira</i> , <i>Neospora</i> , <i>Chlamydia pecorum</i>
	Fresh liver	Nutritional analysis (trace minerals, vitamin A/E)
	Stomach contents (amniotic fluid analog)	Culture
	Fetal thoracic fluid (fetal serum analog)	Serology (Bluetongue virus, Border disease virus, Cache Valley virus)
Placenta	Fresh and fixed	Histopathology, culture, small ruminant abortion panel PCR
Maternal serum	Fresh/frozen	Serology (Bluetongue virus, Border disease virus, Cache Valley virus, OPP/CAE), trace minerals, vitamin A/E