



Vet Pulse

IMPORTANT INFORMATION FOR OUR REFERRING VETERINARIANS

I Can See Clearly Now, the Cataract is Gone

by Dr. Rachel Allbaugh, Diplomate ACVO, and Dr. Braidee Foote, Ophthalmology Resident

Iowa State University is excited to announce that we recently purchased the most advanced technology for cataract removal available.

The Stellaris Elite phacoemulsification machine is at the top of its class for human and veterinary cataract surgery. It is best known for stabilizing intraocular pressure during surgery, creating a highly responsive and controlled surgical environment and improving lens removal efficiency. This leads to a faster, safer surgery and decreases complications.

Are you wondering which patients should be referred for cataract surgery? A patient with any size or stage of cataract is a good candidate to refer for evaluation; then based on the ophthalmic exam, we will discuss the indication for surgery.

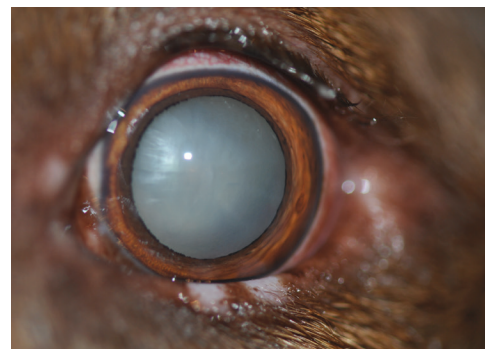
Drs. Rachel Allbaugh and Rita Wehrman performing bilateral cataract surgery on a diabetic dog with the Stellaris Elite Phacoemulsification Machine.

In predisposed purebred dogs or diabetic patients, even the presence of incipient (or small) cataracts warrants initial evaluation so that the client can meet an ophthalmologist and establish a relationship for monitoring.

The late immature cataract is the ideal stage for cataract surgery, when vision is impaired, but secondary changes inside the eye have not yet occurred.

Many mature and hypermature cataracts are operable; however eyes with advanced lens-induced uveitis causing secondary blinding glaucoma, retinal detachment, and/or retinal degeneration are unfortunately not candidates for surgery. Early referral minimizes the chance of these risks developing, but if present, we can still help improve comfort for your patient.

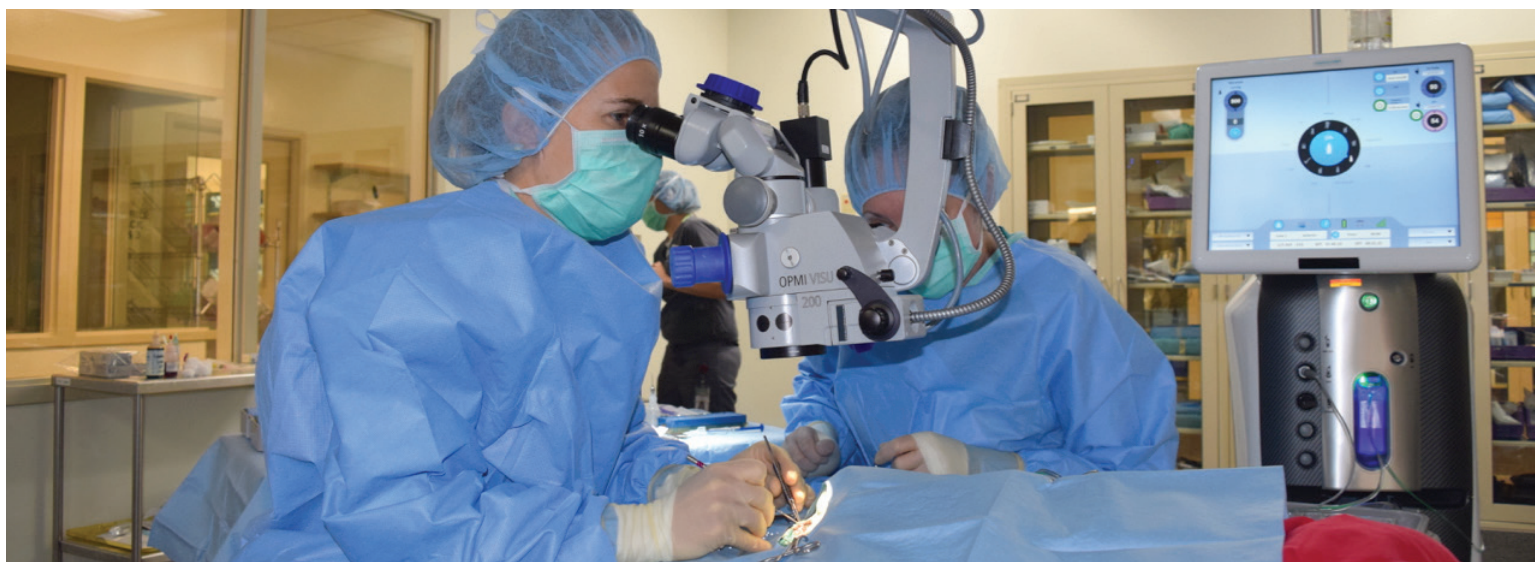If you note a rapidly progressing cataract or a cataract patient with secondary inflammation (noted by blepharospasm,



Mature cataract in a dog after dilation with tropicamide for full examination

redness or tearing), we recommend immediate referral. When lens-induced uveitis is caught early and treated appropriately, the patient can remain comfortable and a good candidate if surgery is desired.

We look forward to helping your patients see again and remain comfortable! Please reach out to us at (515) 294-4900 for any of your ophthalmic-related needs.



Greetings to our Referring Veterinarians

I am excited to join the Iowa State University College of Veterinary Medicine team as the new Director of Hospital Operations, following in the footsteps of Dr. Tom Johnson, who has retired (yet again). I have been warmly welcomed by many of the IVMA veterinarians already, and am looking forward to meeting more of you as we work toward furthering animal and public health together.

It is an exciting time at the Lloyd Veterinary Medical Center (LVMC). The first phase of the new Pet Cancer Center is underway with the construction of a specialized area for Stereotactic Radiation Therapy (SRT). This is targeted radiation therapy for specific types of solid tumors, allowing for greatly reduced treatment times. The unusual springtime weather slightly delayed the construction, but the SRT is anticipated to be able to treat patients by the end of September through our Oncology Service.

Our Magnetic Resonance Imaging (MRI) unit is undergoing a major scanner upgrade in the month of June. While the MRI will unfortunately not be available during the upgrade, the result will be greatly enhanced images with corresponding diagnostic capabilities through our Radiology (Diagnostic Imaging) Service.

We were pleased at the positive feedback for our Partners-in-Progress continuing education event sponsored jointly by LVMC and Iowa Veterinary Specialties (IVS) in April. The full-day event included three rooms of speakers from LVMC and IVS on a wide variety of topics, and included CE for doctors and technicians. We are looking forward to planning next year's event, and welcome topic suggestions you would find useful.

Thanks to your strong support in referring patients, our caseload is growing. Areas of greatest growth include Emergency/Critical Care, Cardiology, Oncology, Equine Medicine and Surgery, but almost all of our services are in high demand. The use of our Blood Bank is also growing. We are hiring additional support staff, and have added internship and residency positions in several areas to meet the demand and maintain high-quality service for you, our mutual clients, and the patients.

We hope that you enjoy this edition of Vet Pulse. Should you have suggestions for topics to be addressed in future issues, please let us know.

Dr. Stephanie West
Director of Hospital Operations, LVMC



Welcome

The LVMC Hixson-Lied Small Animal Hospital is thrilled to welcome the newest member of our Cardiology Service, Dr. Melissa Tropf. Dr. Tropf joins Drs. Wendy Ware and Jessica Ward as Iowa State's third board-certified cardiologist.

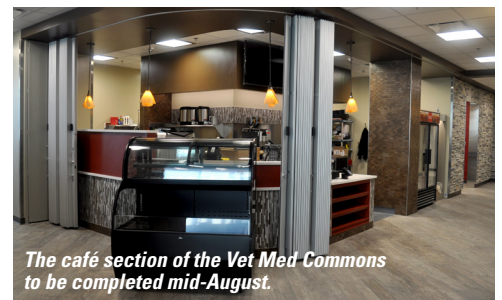

Dr. Tropf is an Ohio native who received her DVM degree from Ohio State University in 2011. She then completed her internship, Cardiology residency, and master's degree at Washington State University, and became board-certified by the American College of Veterinary Internal Medicine in 2016.

Most recently, Dr. Tropf has served as a clinical faculty member at Purdue University. Dr. Tropf has a strong interest in teaching and mentoring both veterinary students and house officers (interns and residents). She is excited to join our team at Iowa State and looks forward to serving our patients, clients, and referring veterinarians!

GOING TO THE IVMA FALL CONFERENCE IN SEPTEMBER?

The Thursday night reception on Sept. 20 will be held in the newly renovated Vet Med Commons at ISU. IVMA members will also have access to the new Pet Cancer Center and Stereotactic Radiation Therapy service, and other new areas of the college and hospitals.



The café section of the Vet Med Commons to be completed mid-August.

Equine Program Receives Equipment Grant

The Fullgraf Foundation has committed \$403,000 to Iowa State University's College of Veterinary Medicine to purchase equipment and support veterinarians in residency at the college's Lloyd Veterinary Medical Center.

Support for Equipment

A grant of \$153,000 allowed the College of Veterinary Medicine to purchase much-needed equipment for the equine surgery section. This included a fluoroscopy unit (C-arm), an imaging modality that uses X-rays to produce a real-time image of anatomy.

"The ability to offer imaging in real time becomes critical in equine surgery," said Dr. Stephanie Caston, associate professor of veterinary clinical sciences. "The fluoroscopy unit will be used in surgery to ensure that the surgical procedure is proceeding correctly, for instance when we are repairing fractures we can ensure that implants are placed where desired and the fracture is aligned correctly."

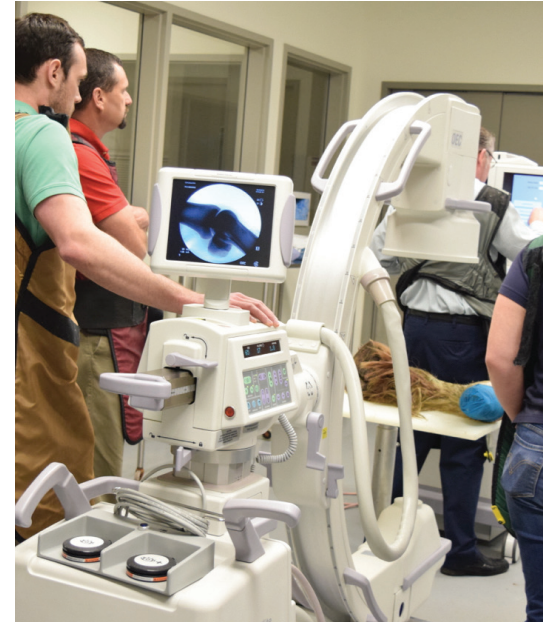Other equipment purchases will include a locking compression plate, a videoendoscopy unit and an arthroscopy fluid pump.

Equine Resident Support

A \$250,000 grant establishes the Charlotte Stone Fullgraf Equine Surgery Resident's Research and Support Fund.

The Charlotte Stone Fullgraf Equine Surgery Resident's Research and Support Fund will provide annual funding for two equine surgery residents to help cover research project expenses and continuing education costs.

"Currently, our residents must either apply for research grants in hopes for funding for their project, pay for their own project or be a part of a project that is funded by one of our senior clinicians," said Dr. Kevin Kersh, clinical associate professor. Research projects are a requirement of the equine surgery program. "This new fund will also significantly defray costs borne by our surgical residents for attending continuing education and advanced training meetings."



The Fullgraf Foundation is under the direction of Jan Fullgraf Golann and Charles S. Fullgraf. The Charlotte Stone Fullgraf Equine Surgery Resident's Research and Support Fund honors Charles' and Jan's mother, Charlotte, who graduated in 1946 from Iowa State University with a major in dietetics, and died in 2008.



SRT Update

Work is progressing on the Stereotactic Radiation Therapy project, with anticipated opening of the SRT unit in fall of 2018.


IOWA STATE UNIVERSITY

Lloyd Veterinary Medical Center

1809 S Riverside Drive | Ames, IA 50011-3619

CONNECT WITH US

Hixson-Lied Small Animal Hospital
(515) 294-4900

 /iowastateuniversityveterinaryhospital

Equine & Food Animal Hospital
(515) 294-1500

 /iowastateuniversitylargeanimalhospital

To view an electronic version of
Iowa State University Vet Pulse visit:
vetmed.iastate.edu/VetPulse

IOWA STATE UNIVERSITY
Lloyd Veterinary Medical Center

Vet Pulse

INSIDE THIS ISSUE:

- 1 Cataract Surgery
- 2 Message from Director
- 3 Equine Surgery Receives Equipment Grant
- 4 MRI Gets Upgrade

PRODUCTION STAFF

Tracy Ann Raef, Editor/Writer
Heather Brewer, Designer

For article inquiries or submissions email:
VetPulse@iastate.edu

Iowa State University does not discriminate on the basis of race, color, age, ethnicity, religion, national origin, pregnancy, sexual orientation, gender identity, genetic information, sex, marital status, disability, or status as a U.S. Veteran. Inquiries regarding non-discrimination policies may be directed to Office of Equal Opportunity, 3410 Beardshear Hall, 515 Merrill Road, Ames, Iowa 50011, Tel. 515 294-7612, Hotline 515-294-1222, email eooffice@iastate.edu

Upgrade Extends Life, Image Quality of MRI

Our powerful Magnetic Resonance Imaging (MRI) machine was installed in 2007. At the heart of the unit is the 1.5 Tesla GE Signa magnet, built to last for at least 30 years. Unfortunately, the software to run the system doesn't last nearly as long. With nearly two decades of magnet life remaining, the end-of-life date for the MRI software and electronics was drawing near.

REPLACE OR UPGRADE?

Purchase of a new 3 Tesla MRI and associated construction costs to accommodate it would be about \$4 million. For a quarter of the cost and about a month of offline time, we could modernize and upgrade the current unit to extend its useful life.

The decision was made to upgrade the current equipment, rather than replace the expensive unit. The MRI was taken offline on May 31 to prepare for the major upgrade. New electronics required construction to rework the existing space for the upgrade. The construction,

software installation process, testing and training is expected to be completed shortly, with the upgraded MRI fully operational in mid-July.

"We're really excited about the upgrade and its benefits," said Dr. Kristina Miles, associate professor of radiology. "Our scan times will be faster, and the image quality will be improved because of the better signal-to-noise ratio. Our upgrade also includes software to enable 3D neuro-imaging, and diffusion tensor imaging which is effective for detecting nerve damage in the brain and disease processes that involve small blood vessels.

The upgraded MRI will have a suite of new flexible coils that will accommodate a variety of patient shapes comfortably, and provide easier patient handling.

"We'll also receive off-site support from GE applications specialists and our radiology service will receive on-site training," Dr. Miles added.